

# Cat Studies of Francis Pottenger, 1935-1940

1

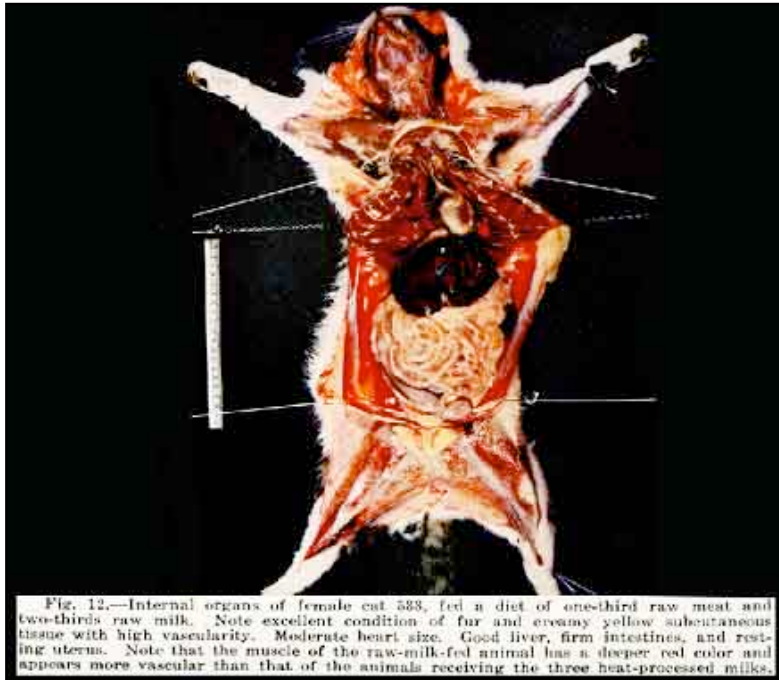


Fig 12. Internal organs of a female cat fed diet of one-third raw meat and two-thirds raw milk. Note excellent condition of fur and creamy yellow subcutaneous tissue with high vascularity. Moderate heart size. Good liver, firm intestines and resting uterus.

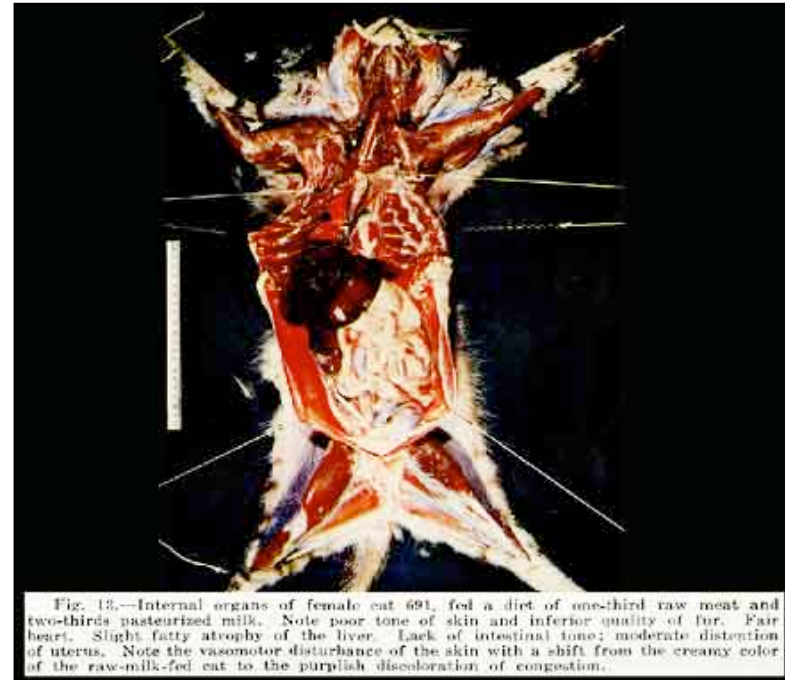


Fig 13. Internal organs of female cat fed diet of one-third raw meat and two-thirds pasteurized milk. Note poor tone of skin and inferior quality of fur. Fair heart. Slight fatty atrophy of the liver. Lack of intestinal tone; moderate distention of the uterus. Skin has a purplish discoloration due to congestion.

*Francis Pottenger lecture for Randleigh Farms.*